926

Mosaic trisomy 2 identified via whole-genome cfDNA screening

Theresa Boomer, MS, CGC, CG/MB(ASCP)[cm1], Marney Brillinger, MS, CGC[2], Samantha Caldwell, MS, LCGC[1], Erica Soster, MS, LCGC[1], Ron McCullough, PhD, MBA[1]
[1]Sequenom®, Inc./Integrated Genetics, Laboratory Corporation of America® Holding, [2]Brigham & Women's Maternal Fetal Medicine, Boston, MA

Integrated GENETICS
LabCorp Specialty Testing Group
sequenom

I. Objective

Esoteric aneuploidy (non-trisomy 13/18/21) detection via expanded cell-free DNA (cfDNA) prenatal screening presents several unique caveats; they are relatively common, often confined to the placenta, and have variable clinical impact.[1-6] Herein we describe one of very few clinical reports of mosaic trisomy 2, in addition to the first and only cfDNA identified case of a true fetal mosaic trisomy 2 in the medical genetic literature.

II. Study Design

The maternal blood sample was subjected to DNA extraction, library preparation, and genome-wide massively parallel sequencing.[7] Sequencing data were analyzed using a novel algorithm to detect trisomies and subchromosomal, genome-wide copy number variants 7Mb and larger.[8]

III. Results

The patient presented to Maternal Fetal Medicine clinic at 10.7 weeks' gestation for genetic counseling and routine ultrasound. Advanced maternal age and a prior trisomy 8 pregnancy prompted expanded cfDNA screening, ultimately yielding a trisomy 2 result (~65% mosaicism, 6% fetal fraction) and residual risk for uniparental disomy (UPD) (see **Image 1**).[9] Amniocentesis inclusive of single nucleotide polymorphism (SNP) microarray testing was recommended to assess both trisomy and UPD risk.

Trisomy 2 is a relatively common finding per placental literature, usually confined to the mesenchyme, and carries an exceedingly low risk for true fetal mosaicism.[10-13] A limited number of published confirmed trisomy 2 case studies was a substantial counseling limitation, noted for highly variable outcome data (see **Table 2**).[14-24]

Chorionic villus sampling (CVS) was declined and fetal ultrasound showed normal growth and nuchal translucency measurement at 10.7 weeks. However, a subsequent scan at 16 weeks showed a 2 vessel cord and a 1 week lag in humerus/femur length, increasing to a 2 week lag by 18 weeks. Fetal echocardiogram showed hypoplastic left ventricular output (LVOT) and possible coarchtation of the aorta. Amniocentesis at 20 weeks with SNP microarray revealed 23% mosaicism for Trisomy 2 and normal bi-parental inheritance, ruling out UPD. The pregnancy continued with growth lag measuring 5 weeks behind at 33 weeks. Palliative care was discussed, as prognosis was guarded.

Premature rupture of membranes (PROM) at 34.4 weeks prompted delivery of a 3 lbs, 6oz (0%) neonate with APGARs of 2 and 8. An extended NICU stay ensued, with clinical outcome exceeding expectations. No confirmatory postnatal genetic testing was found on record and presumably was felt of limited utility given the concordant cfDNA and amniocentesis results, multiple congenital anomalies, and the limitation mosaicism poses with variable tissue specificity. Head ultrasound and MRI shortly after birth were essentially normal, consistent with prematurity. A large atrial septal defect (ASD) was repaired at 5 months of age, resolving post right ventricular hypertension and right ventricular systolic dysfunction.

Now approaching age three, the child is reportedly doing well overall. Her last clinic measurements showed improvement in growth and size, measuring 11th% height, 2nd% weight, and 30th% head circumference. Endocrinology consultation was favorable, finding no pathology and normal growth velocity. Mild axial hypotonia persists, while once delayed motor skills are now deemed on target. A persistent heart murmur is noted. Ophthalmology continues to follow the child for high hyperopia, that is improving.

Image 1. Genome wide overview of cfDNA trace data. Note elevation of chromosome 2

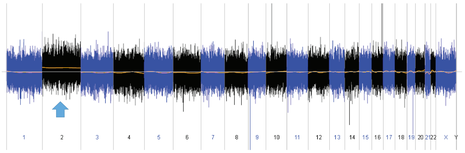

Table 1. Summary of our 6 total reported cfDNA Trisomy 2 samples

Case	Gestational Age	Indication for testing	cfDNA Reported Result	Confirmatory Testing				Final Outcome
				CVS	Amnio	Postnatal	Ultrasound Findings	
1*	10 weeks	AMA and prior trisomy	Mosaic T2 (65%)	X	Microarray: 20% Trisomy 2 on direct SNP array; 23% Trisomy 2 final result inclusive of cultured cells. Additional back-up cultures for expanded counts failed to grow.	X	2 vessel cord, IUGR, fetal echo showed hypoplastic left ventricular output (LVOT) and possible coarctation of the aorta	Delivery at 34 weeks GA, 3 lbs, 6 oz (1531g). Small size, hypotonia, large ASD, high hyperopia, otherwise normal development at 2.5 yrs
2	11 weeks	AMA	Non-mosaic T2	X	X	?	At 32 weeks GA noted to be small for gestational age	Delivered at outside facility; lost to follow-up
3**	10 weeks	AMA	Non-mosaic T2	X	Microarray: 24% Trisomy 2 on direct SNP array; normal karyotype.	?	IUGR	Delivered at 37 weeks GA, 3 lbs, 1 oz, APGARS 8 & 9, non-dysmorphic without anomalies
4	11 weeks	AMA, USF (NOS)	Low mosaic T2 (23%)	X	Karyotype and microarray 'normal', biparental inheritance	?	?	?
5	16 weeks	AMA	Non-mosaic T2	X	X	?	Composite growth good (39%) with persistent short femur length; normal fetal echo, normal anatomy	Full term delivery at outside facility; lost to follow-up
6	10 weeks	AMA	Non-mosaic T2	Non-mosaic Trisomy 2	FISH: normal; cultured cells: 12% Trisomy 2 mosaicism	X	Severe IUGR noted at 16 weeks GA	TAB

*Current case
**MaternIT® 21 PLUS sample that was ultimately reported out 'Non-Reportable' with lab director comment noting overt Trisomy 2.

Table 2. Literature review of Amniocentesis confirmed Trisomy 2 cases. Table adapted from Tuğ E et al (2017).[14-24]

Reference	Indication	Mosaic trisomy 2 in amniocentesis (% T2)	Mosaic trisomy 2 in confirmation studies	Outcome	Clinical findings
Sago et al.	Elevated MSAFP, Prenatal USG: IUGR, DORV, ASD, VSD, hydronephrosis	22.6% (31 cells)	Blood: 0% (100 cells) Skin: 0% (100 cells) Ascites: 0% (100 cells) Intestine: 0% (39 cells) Liver: 4% (100 cells) Skin: UPD2 excluded	Delivery at 30 weeks: 1135 g	SGA, hypotonia, microcephaly, growth retardation, developmental delay, prominent occiput, beaked-prominent nose, flat malar area, thin lip, pointed chin, pectus excavatum, inguinal hernias, V-shaped palate, rocker-bottom feet, congenital heart defects, hydronephrosis, vesicoureteral reflux, delay myelination, a thin corpus callosum, hippocampal dysplasia, portal fibrosis.
Webb et al.	AMA, Trisomy 2 at CVS, Prenatal USG: Oligohydramnios	Culture A: 23.3% (30 cells) Culture B: 0% (30 cells)	Cordocentesis: 0% (100 cells) Blood: 0% (100 cells) Placenta: 100% (120 cells) Skin: 0% (100 cells) Maternal UPD2	Delivery at 31 weeks: 765 g	Normal development, PDA, congenital pyloric stenosis, sliding hiatal hernia, vesicoureteral reflux, No obvious dysmorphic features
Hsu et al.	AMA	4% (52 cells)	Blood: 0% (79 cells) Placenta: 0% (52 cells)	Normal liveborn	
	Elevated MSAFP	6.3% (32 cells)	Placenta: 25% (20 cells)	Stillbirth	No visible birth defects
	NA	6.7% (30 cells)	Placenta: 25% (20 cells)	IUFD	
	Elevated MSAFP	33.3% (30 cells)	Lung: 13.3% (30 cells) Placenta: 20% (30 cells) Skin: 0% (50 cells) Skin: 0% (50 cells)	TAB	Abnormal abortus, dolichocephaly, oligohydramnios
	NA	20% (40 cells)	NA	Stillbirth	
Robinson et al.	Abnormal MSS for AFP and hCG, Down risk: 1/90	Culture A: 36.7% (30 cells) Culture B: 50% (30 cells) Culture C: 83.3% (30 cells)	Skin (right): 4% (100 cells) Kidney (right): 3.9% (77 cells) Adrenal (right): 7% (100 cells) Brain: 0% (35 cells) Heart: 3.9% (77 cells) Testis: 4% (100 cells) Cord blood: 0% (100 cells) Cord: 1% (100 cells) Placenta (site 1): 73.3% (30 cells)	TAB	Mild dysmorphic features, absent gall bladder, cystic left kidney, 13th left rib, Mild unilateral talipes
Chen et al. (2012)	AMA, Prenatal USG: Severe IUGR, oligohydramnios	Amniocentesis (1st): 0% (25 cells) Amniocentesis (2nd): 0% (19 cells) aCGH: mosaic T2 on Interphase FISH: 12% (50 cells)	Amnion: 7.5% (50 cells) Cord: 0% (60 cells) Blood: 0% (100 cells) Placenta: complete T2 (aCGH) Skin: disomy 2 (aCGH, QF-PCR) UPD2 excluded	Delivery at 26 weeks: 488 g, Neonatal death	SGA, low-set ears, macroglossia, clenched hands
Chen et al. (2013)	Abnormal MSS for hCG and MSPAPP-A; Down risk: 1/12; NT: 2.2 mm, Severe oligohydramnios, IUGR and VSD	Amniocentesis: 26% (30 cells) aCGH: no genomic imbalance	Interphase FISH: 11.1% (130 cells) Amnion: 0% (21 cells) Cord blood: 0% (40 cells) Skin: 0% (40 cells) Lung: 0% (40 cells) Liver: 1% (40 cells) Umbilical cord: 1% (40 cells) Amniotic membrane: 50% (40 cells) Placenta: 100% (40 cells) QF-PCR: UPD2 excluded	TAB at 22 weeks: 420 g	Micrognathia, depressed nasal bridge, low-set ears and preaxial polydactyly of the right hand
Chen et al. (2011)	AMA	Amniocentesis: 5% (20 cells) aCGH: no genomic imbalance	Interphase FISH: 3% (100 cells) QF-PCR: UPD2 excluded. Amnion: 0% (32 cells) Cord blood: 0% (40 cells) Interphase FISH urinary cells: 3.9% (107 cells)	Delivery at term: 3400 g	No phenotypic abnormalities, normal growth and psychomotor development at 1 month of age
Chen et al. (2013)	Abnormal MSS for AFP, uE3, total β-hCG and inhibin-A; Down risk: 1/149	Amniocentesis (1st): 4.5% (22 cells) Amniocentesis (2nd): 0% (20 cells) aCGH: no genomic imbalance Interphase FISH: 23.4% (47 cells) QF-PCR: UPD2 excluded Amniocentesis (3rd): 0% (30 cells) Interphase FISH:9.4% (53 cells)	Cord blood: 0% (40 cells) Interphase FISH in urinary cells: 8.2% (49 cells)	Delivery at term: 3316 g	Normal development, no phenotypic abnormalities
Tuğ E et al.	AMA, Abnormal MSS, Down risk: 1/50 Prenatal USG: SUA, cardiac dextroposition and diaphragmatic hernia	Amniocentesis: 14% (85 cells) Culture A: 25% (16 cells) Culture B: 27% (22 cells) Culture C: 0.5% (34 cells)	Cordocentesis: 0.04% (25 cells) Repeated amniocentesis: 19.35% (6 cells) Culture A: 1% (11 cells) Culture B: 33.3% (20 cells)	TAB	NA
Sifakis et al.	AMA	Amniocentesis: Cultured amniocytes showed 47,XY,+2[1]/46,XY[21]. 22 colonies total revealed one colony with three cells total, all showing trisomy 2.	Repeat amniocentesis with FISH on uncultured cells revealed trisomy 2 in 6/112 (5.3%), aCGH on uncultured cells revealed no genomic imbalance, and QF-PCR excluded uniparental disomy 2. Cultured cells revealed 46,XY in all 20 colonies examined. Cord blood at delivery revealed 46,XY in 40/40 cells.	Delivery at 38 weeks: 2906 g	Non-dysmorphic infant with normal development at age 2
Chen et al. (2017)	AMA, CVS: 47,XY,+2[34/34] cultured cells, uncultured cells 14%	Amniocentesis: 26/27 colonies 46,XY, one colony with one cell 47,XY,+2. Uncultured aCGH analysis < 10% mosaicism Trisomy 2; interphase FISH 5.6% [6/107] Trisomy 2 cells, and QF-PCR excluded uniparental disomy 2.	Cordocentesis 0% [25/25]; postnatal uncultured urinary FISH analysis @ 2 weeks showed 9.7% [13/134] trisomy 2, and @ 6 months 6% [3/50].	Delivery at 39 weeks: 3048 g	Phenotypically normal male

IV. Conclusion

While many esoteric trisomies remain confined to the placenta and are of variable clinical consequence, the risk for true and occult fetal mosaicism cannot be dismissed. This case report illustrates the first known cfDNA identified, amnio confirmed true fetal mosaic for trisomy 2.

Key Findings

- Whole-genome cfDNA screening can detect esoteric autosomal trisomies (e.g. Trisomy 2) that have variable clinical impact on placental function and risk for true fetal mosaicism, necessitating a high risk obstetrical approach to pregnancy management. (see **Table 1**)
- Trisomy 2 is a common mosaic placenta finding in CVS, is typically confined to the placenta and associated with IUGR, but carries a small risk for true fetal mosaicism and UPD.
- Although CVS testing offers important placental insight in cases such as these, amniocentesis testing is ultimately necessary to clarify fetal risk.

V. References

1. Soster E et al. Esoteric aneuploidies and genome-wide cell-free DNA. Poster presentation at NSGC 2017.
2. Ehrich M et al. Genome-wide cfDNA screening: clinical laboratory experience with the first 10,000 cases. *Genet Med.* 2017; 19(1332).
3. Pertile MD et al. Rare autosomal trisomies, revealed by maternal plasma DNA sequencing, suggest increased risk of feto-placental disease. *Sci Transl Med.* 2017; 9(405).
4. Soster E et al. Clinical outcomes of genome-wide cfDNA for cases screening positive for trisomies 3,7,15,16, and 22. Poster presentation at ISPD 2018.
5. Van Opstal D et al. Origin and clinical relevance of chromosomal aberrations other than the common trisomies detected by genome-wide NIPS: results of the TRIDENT study, *Genet Med*. Vol 20, pg 480–485 (2018).
6. Boomer T et al. Genome-wide cfDNA screening: Trends and lessons from >40,000 samples. Poster presentation at ISPD 2018.
7. Jensen T et al. High-throughput massively parallel sequencing for fetal aneuploidy detection from maternal plasma. *PLoS One.* 2013; 8(3):e57381. doi:10.1371/journal.pone.0057381. Epub 2013 Mar 6.
8. Lefkowitz RB et al. Clinical validation of a non-invasive prenatal test for genome-wide detection of fetal copy number variants. *Am J Obstet Gynecol*. doi: http://dx.doi.org/10.1016/j. ajog.2016.02.03.
9. Wardrop J et al. Mosaicism Ratio in cfDNA Testing: A Potential Tool to Identify Discordant Results. Poster presented at: 2017 ACMG Annual Clinical Genetics Meeting, 2017 Mar 21-25; Phoenix, AZ.
10. Grati F et al. Chromosomal Mosaicism in Human Feto-Placental Development: Implications for Prenatal Diagnosis. *J Clin Med.* 2014; 3(3):809-37. Published 2014 Jul 24. doi:10.3390/jcm3030809.
11. Editors McKinley Gardner RJ, Sutherland GR. Chromosome abnormalities and genetic counseling. Oxford: Oxford University Press (3rd edn.) 2003:25, 392-432. ISBN 0 195 14960 2 (hardback).
12. Kalousek DK. Pathogenesis of chromosomal mosaicism and its effect on early human development. *Am J Obstet Gynecol*. 2000;91(1).
13. Robinson WP et al. Meiotic origin of trisomy in confined placental mosaicism is correlated with presence of fetal uniparental disomy, high levels of trisomy in trophoblast, and increased risk of intrauterine growth restriction. *Am J Hum Genet*. 1997; 60(4).
14. Tuğ E et al. (2017) Confirmation of the prenatal mosaic trisomy 2 via fetal USG and cytogenetic analyses, *J Matern Fetal Neonatal Med*, 30:13, 1579-1583, doi:10.1080/14767058.2016.1214700.
15. Chen CP et al. Prenatal diagnosis of mosaic trisomy 2 associated with abnormal maternal serum screening, oligohydramnios, intrauterine growth restriction, ventricular septal defect, preaxial polydactyly, and facial dysmorphism. *Taiwan J Obstet Gynecol* 2013; 52:395–400.
16. Chen CP et al. Prenatal diagnosis of mosaic trisomy 2: discrepancy between molecular cytogenetic analyses of uncultured amniocytes and karyotyping of cultured amniocytes in a pregnancy with severe fetal intrauterine growth restriction. *Taiwan J Obstet Gynecol* 2011; 50:390–3.
17. Chen CP, et al. Application of interphase FISH on uncultured amniocytes for rapid confirmation of true trisomy 2 mosaicism in the case of suspected amniocyte mosaicism involving trisomy 2 in a single colony. *Taiwan J Obstet Gynecol* 2013; 52:300–2.
18. Chen CP et al. Mosaic trisomy 2 at amniocentesis: prenatal diagnosis and molecular genetic analysis. *Taiwan J Obstet Gynecol* 2012; 51:603–11.
19. Robinson J, Stewart H, Moore L, Gaunt L. A case of mosaic trisomy 2 diagnosed at amniocentesis in an abnormal fetus and confirmed in multiple fetal tissues. *Clin Genet* 1997; 51:417–20.
20. Sago H et al. True trisomy 2 mosaicism in amniocytes and newborn liver associated with multiple system abnormalities. *Am J Med Genet* 1997; 72:343–6.
21. Hsu LYF et al. Rare trisomy mosaicism diagnosed in amniocytes, involving an autosome other than chromosomes 13, 18, 20, and 21: karyotype/phenotype correlations. *Prenat Diagn* 1997; 17:201–42.
22. Webb AL et al. Maternal uniparental disomy for chromosome 2 in association with confined placental mosaicism for trisomy 2 and severe intrauterine growth retardation. *Prenat Diagn* 1996; 16:958–62.
23. Chen CP et al. Prenatal diagnosis of mosaicism for trisomy 2 in a single colony at amniocentesis in a pregnancy with a favorable outcome. *Taiwan J Obstet Gynecol*, Volume 56, 2017.
24. Sifakis S et al. 2004. Prenatal diagnosis of trisomy 2 mosaicism: a case report. *Fetal Diagn Ther* 19:488-490.

LabCorp

©2019 Laboratory Corporation of America® Holdings. All rights reserved. rep-1291-v1-0119

MaternIT® is a registered trademark of Sequenom, Inc. Sequenom, Inc. is a wholly owned subsidiary of Laboratory Corporation of America® Holdings.
Integrated Genetics is a brand used by Esoterix Genetic Laboratories, LLC, a subsidiary of Laboratory Corporation of America® Holdings.
Poster presented at the ISPD 19th Annual Pregnancy Meeting; 2019 February 21-24; Las Vegas, NV.